

Isolated Medial Rectus Cysticercosis mimicking pre-septal cellulitis: A Case Report

Dr. Pooja choudhary¹, Dr. Arvind Chauhan², Dr. Manoj Verma^{3§}

¹Senior Resident, Department of Ophthalmology, AIIMS, Jodhpur (Rajasthan) India

²Professor and Head, Department of Ophthalmology, SN Medical College, Jodhpur (Rajasthan) India

³Senior Resident, Department of Community Medicine, AIIMS, Jodhpur (Rajasthan) India

[§]Corresponding author's Email: manojverma300@gmail.com

Abstract— *Man is the intermediate host in the life cycle of the pork tapeworm Taenia solium. Its larval form Cysticercus cellulosae is the causative agent of cysticercosis. Both intraocular and extra ocular cysticercosis is observed in tropical countries like India. A case of extra ocular cysticercosis is reported here. An eight year old female patient who was brought to emergency department with pain and swelling around peri-orbital region, diminution of vision along with ptosis in left eye. CT scan showed scolex of Taenia solium in left medial rectus muscle. The patient recovered completely with oral albendazole steroids for four weeks. So a case with pain and swelling around peri-orbital region, diminution of vision along with ptosis in left eye should be investigated for cysticercosis.*

Keywords: *Taeniasis, Extra ocular Cysticercosis, Medial Rectus, Peri-Orbital Region.*

I. INTRODUCTION

Cysticercosis is the most common parasitic disease of the nervous system¹ caused by *Cysticercus cellulosae*, the larval form of *Taenia solium*. Man gets infested by accidental ingestion of *Taenia solium* eggs, through faecally contaminated water or food or under cooked pork and man acts the intermediate host for that.² *Cysticercus cellulosae* could be found in encysted form in various body tissues, including the eyes, central nervous system (CNS), and subcutaneous tissues. Ocular cysticercosis is known to be endemic in tropical region of sub-Saharan Africa, India and East Asia.³ In ocular cysticercosis, the most common site of involvement is reported to be vitreous and sub-retinal tissue,⁴ while extra ocular muscle cysticercosis is less common.

II. METHODOLOGY

A rare case of Ocular cysticercosis presented with pain and swelling around peri-orbital region, diminution of vision along with ptosis in left eye. On CT scan scolex of *Taenia Solium* was found in left medial rectus muscle. As it is a very rare case. So case was studied thoroughly and case report was prepared to publish this rare case.

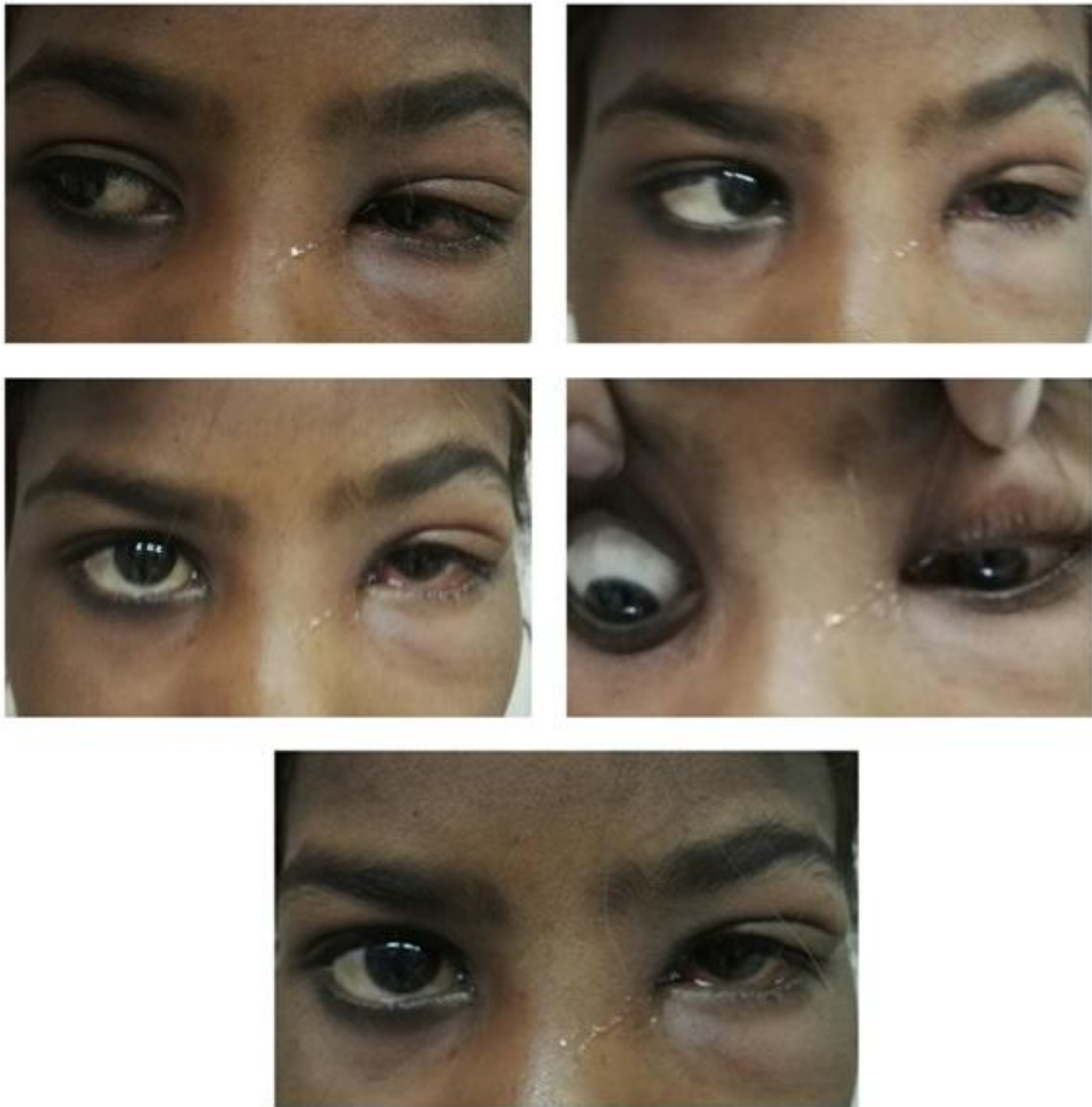III. CASE REPORT

An eight year old female patient was brought to the emergency department of a tertiary care centre of northern India; with complain of pain, swelling of left eyelids, redness of left eye along with diminution of vision from last 6 days. Detailed history was obtained from her parents, who gave no history of any local trauma to eye, or any insect bite and there was no history of fever or vomiting. Patient belonged to lower socio-economic class and was non-vegetarian. No other significant history was revealed. Symptoms of patient inclined the differential toward infective pathology.

On local examination of left eye, both eyelids had oedema along with ptosis of upper eyelid (due to oedema) was present mimicking pre-septal cellulitis. Congestion and chemosis was seen on nasal and inferior conjunctiva. Diplopia on lateral gaze of left eye was found along with restriction of left eye

abduction, limitation of superior and inferior extra ocular movements with normal movement medially. Patient also complained of pain during eye movement. Restriction of movement ruled out the initial presumptive diagnosis of pre-septal cellulitis. (Figure 1).

Figure 1
Clinical photographs of patient of orbital cysticercosis at different gaze (Day 1)

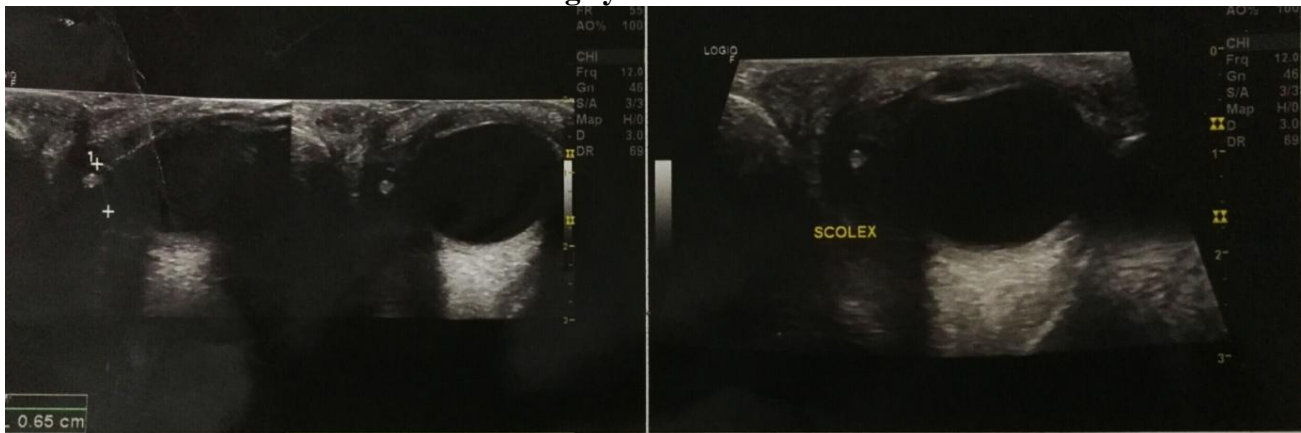

Vision was assessed using Snellen chart and was found to be OD 6/6 and OS 6/18. Pupillary reaction was normal in both eyes. IOP as assessed by Goldman applanation Tonometry was found to be within normal range. Fundus examination did not reveal any significant abnormality. No other sign of neurological involvement was found on clinical examination.

Limitation of eye movement with normal vision, normal pupillary reaction, normal IOP and no abnormality on fundus examination prompted us to think of possible space occupying lesion in the orbit, like leukemic infiltrate, lymphoma, other congenital malignancy, inflammatory lesion etc. An Ultrasonography (USG) of Orbit was advised to detect any space occupying lesion. USG (B scan) orbit

revealed bulky left medial rectus and a 6 mm thin walled cystic lesion in left medial rectus with an internal scolex pointing towards diagnosis of Myocysticercosis (Figure 2).

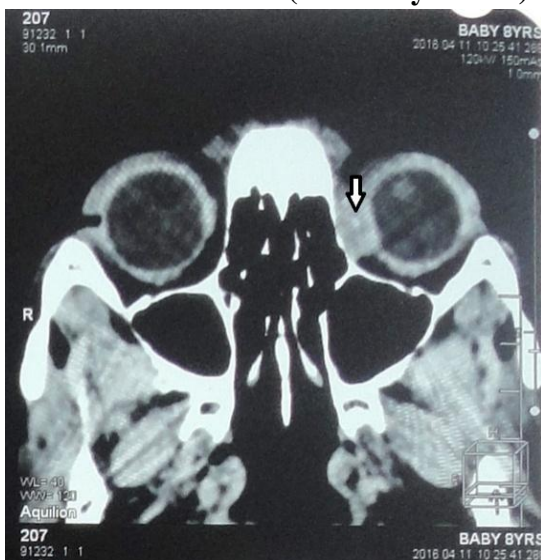
Figure 2
Ultrasound B Scan showing cyst with scolex in left medial rectus



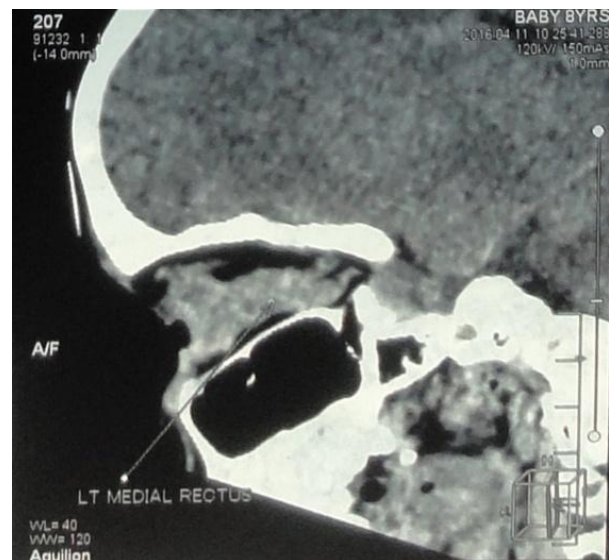
A CT scan of orbits and Brain was planned for further confirmation of diagnosis and to detect any associated intracranial lesions. CT orbit revealed hypertrophy of medial rectus in left eye with 6mm thin walled cystic lesion with a tiny area of increased attenuation within the lesion which is pathognomic of scolex. CT (Computerized Tomography) of brain showed no abnormal finding. Other Routine Blood investigations like CBC, plasma blood sugar were within normal range. (Figure 3).

Figure 3

A:CT Scan (orbit) showing cyst with scolex in medial rectus muscle (shown by arrow)

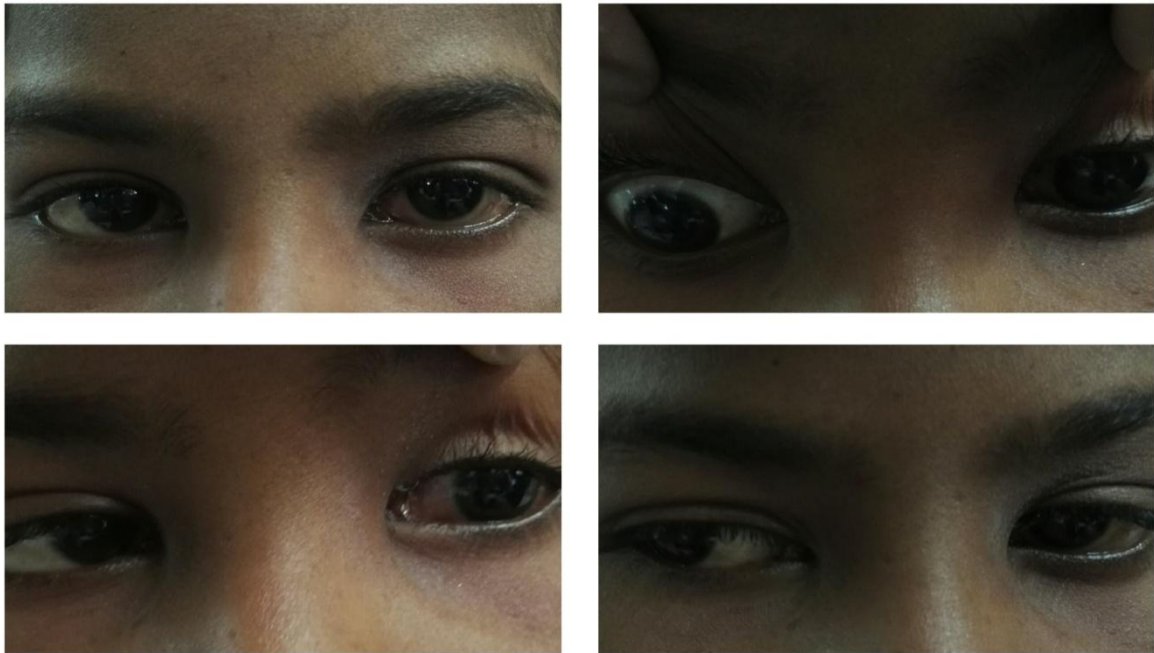


B:CT scan (Sagittal plan) showing hypertrophy of left medial rectus



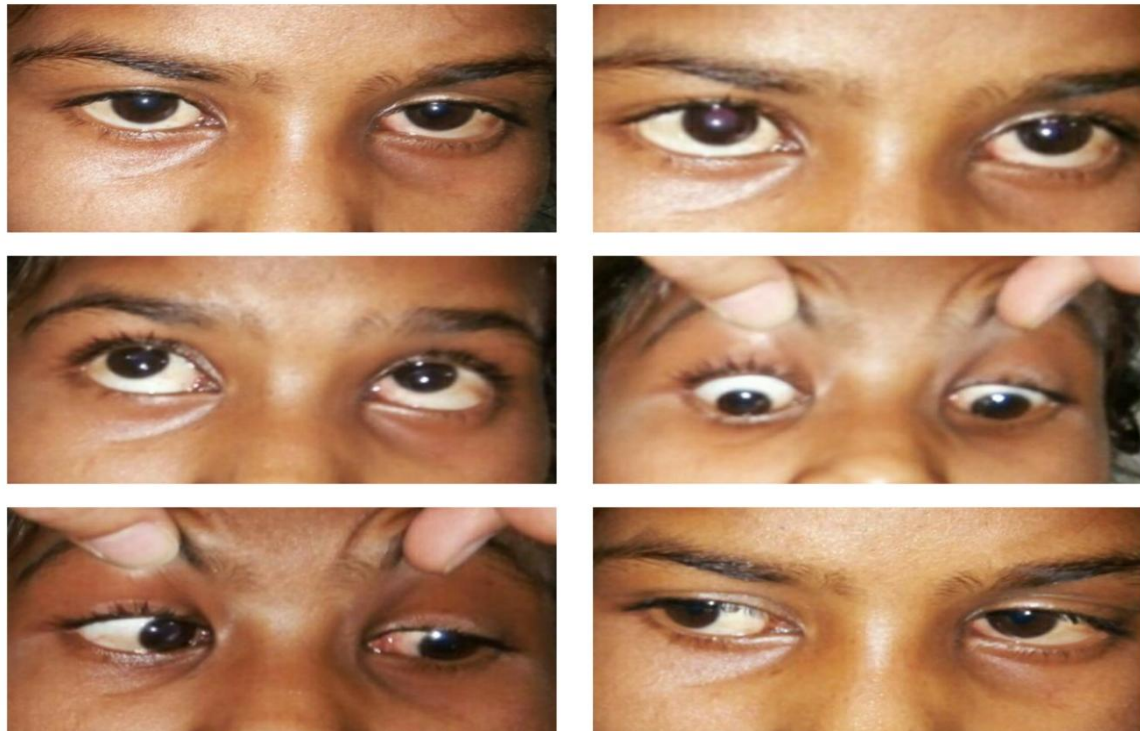
On the basis of above investigations, diagnosis of extra ocular cysticercosis was made. On further probing patient gave history of eating pork which could have been undercooked and resulted in entry of *Cysticercus cellulosae*. Patient was started on oral albendazole (15 mg/kg/day) in conjunction with oral steroids (1.5 mg/kg/day). The patient responded dramatically and on third day there was resolution of pain, chemosis, congestion and lid oedema (Figure 4).

Figure 4
Clinical photographs of patient (Day 3) on treatment showing improvement



After 14 days, on OPD follow-up, extra-ocular movements were completely normal and visual acuity was OU 6/6 (Figure 5). Albendazole were continued for a period of 4 weeks and oral steroid was tapered over a period of one month. Patient showed complete recovery after one month of treatment.

Figure 5
Clinical photographs of patient of orbital cysticercosis (Day 14) on treatment



IV. DISCUSSION

Ocular cysticercosis can affect almost all eye tissues. Most Common sites of involvement are the vitreous cavity, sub-retinal space and sub-conjunctival space,⁴ however Indian studies have reported Ocular adnexa as most common site.^{5,6} Other less commonly involved structures are extra-ocular muscles and optic nerve. Unilateral involvement is common and any eye may be affected. Multiple cysts may develop in the same or both eye, though bilateral involvement is rare.

The medial rectus muscle was involved in present case. Past studies on myocysticercosis had shown inconsistent results on the most common site of cyst lodgement. Two different studies on myocysticercosis reported inferior rectus⁷ and medial rectus,⁸ as the commonest muscle to get affected. However, the cyst may get lodged in any of the extra-ocular muscles. Cysticercosis is most common parasitic infestation of CNS and ocular involvement can occur with or without brain involvement.⁹ Present case showed ocular involvement with no involvement of brain parenchyma.

Ocular cysticercosis can present with symptoms like decreased vision, pain, recurrent redness in eye, painful yellowish nodular sub-conjunctival mass with surrounding conjunctival congestion or as eyelid nodule. It may rarely present with acquired strabismus, diplopia and painful proptosis.^{10,11} Duane retraction syndrome or Brown syndrome may also be found depending on the involved muscle. Blepharoptosis may also occur due to presence of cyst in the Levator palpebrae superioris –Superior Rectus muscle complex.⁷

Optic nerve is rarely involved¹² and its compression by the lodged cyst may cause decreased vision and disc oedema. If cyst is lodged in Optic nerve, it may produce symptoms related to Optic nerve compression.¹³ The route of entry for larva into the eye is probably through the choroidal vasculature. Other potential sites for entry include the ciliary and retinal blood vessels.

Past studies regarding imaging techniques for diagnosis of myocysticercosis had shown comparable results of ultrasound (B-Scan) and CT scan, with USG reported to be slightly better for detecting scolex.⁷ In yet another study, both MRI and CT were reported to accurately detect scolex.¹⁴ In present case, both USG and CT were able to detect scolex and aided in diagnosis.

Present case was an 8 year old female which is concordant to finding of Reddy *et al.* who reported that 90% of cases occurred below 15 years of age. Mahrotra *et al.*¹⁵ also reported a case showing left eye involvement similar to present case. Surgical excision of orbital cysts was considered the ideal treatment modality and early removal of the cyst had been considered crucial in the management of intraocular cysticercosis,¹⁶⁻¹⁸ because the cyst in its spontaneous course, could lead to blindness.¹⁹ However, deep orbital dissection and difficulty in complete cyst excision because of the surrounding inflammatory response could increase risk of postoperative complications. Past studies like that by R.Sihota *et al.*²⁰ had reported oral albendazole as an effective treatment of extra-ocular cysticercosis, present cases also showed complete recovery with albendazole.

V. CONCLUSION

Cysticercosis is a common clinical condition in developing countries like India. It can even involve the eye and its surrounding structures and clinical presentation can vary depending upon structure involved. Extraocular cysticercosis should be kept in the early differential diagnosis of space occupying lesion of orbit as delay in diagnosis can lead to loss of vision. USG and CT are accurate tools for diagnosis and Albendazole is an effective treatment for orbital cysticercosis.

CONFLICT OF INTEREST

None declared till now.

REFERENCES

- [1] Coker-Vann MR, Subianto DB, Brown P, Diwan AR, Desowitz R, Garruto RM, Gibbs CJ, Gajdusek DC (1981): ELISA antibodies of cysticerci of *Taenia solium* in human populations in New Guinea, Oceania and South East Asia. *Southeast Asian J Trop Med Public Health* 12: 499–505.
- [2] Swatz WG (1956): In: *Medical Parasitology*. New York. McGraw-Hill: 127.
- [3] Kapoor S & Kapoor MS (1978): Ocularcysticercosis. *J Pediatr Ophthalmol Strabismus* 15 : 170 –173.
- [4] Bartholomew RS (1975): Subretinal cysticercosis. *Am J Ophthalmol* 79: 670.
- [5] Malik SRK, Gupta AK, Choudhary S. Ocular cysticercosis. *Am J Ophthalmol* 1968; 66:1168.
- [6] Cano MR. Ocular cysticercosis. In: Ryan SJ (ed.). *Retina*, Vol. 2. St. Louis: CV Mosby, 1989; 583–7
- [7] Sekhar GC & Honavar SG (1999): Myocysticercosis: Experience with imaging and therapy. *Ophthalmology* 106: 2336–2340.
- [8] Puri P & Grover AK (1998): Medical management of orbital myocysticercosis: a pilot study. *Eye* 12: 795–799.
- [9] Das D, Deka S, Islam S, Deuri N, Deka P, Deka AC, et al. Neuro and intraocular cysticercosis: A clinicopathological case report. *Eye and Brain* 2010; 2:39-42.
- [10] Pandey PK, Chaudhuri Z, Sharma P, Bhomaj S. Extraocular muscle cysticercosis: a clinical masquerade. *J. Pediatr Ophthalmol Strabismus* 2000; 37(5):273–8.
- [11] Sekhar GC, Lemke BN. Orbital cysticercosis. *Ophthalmology* 1997; 104(10):1599–604
- [12] Menon V, Tandon R, Khanna S, Sharma P, Khokhar S, Vashisht S, Garg I (2000): Cysticercosis of the optic nerve. *J Neuroophthalmol* 20: 59–60.
- [13] J. L. Goyal, S. Das, S. Kumar, D. Chauhan, U. Baheti, V. Sangit. Retrobulbar Cysticercosis Masquerading as Optic Nerve Glioma. *Orbit* 2007; 26(1):61-3
- [14] Martinez HR, Rangel-Guerra R, Arredondo Estrada JH, Marfil Asonofre J (1995): Medical and surgical treatment in neurocysticercosis: a magnetic resonance study of 161 cases. *J Neurol Sci* 130: 25–34.
- [15] Mehrotra SK, Sofat BK. Ocular cysticercosis. *Indian J Ophthalmol*. 1975; 23(3):39–40.
- [16] Gupta A, Gupta R, Pandav SS, Dogra MR, Joshi K (1998): Successful surgical removal of encapsulated subretinal cysticercus. *Retina* 18: 563–566.
- [17] Natarajan, S., Malpani, A., Nirmalan, P. K., & Dutta, B. (1999). Management of intraocular cysticercosis. *Graefes' archive for clinical and experimental ophthalmology*, 237(10), 812-814.
- [18] Seo MS, Woo JM, Park YG (1996): Intravitreal cysticercosis. *Korean J Ophthalmol* 10: 55–59.
- [19] George AE, Biswas J, Agarwal R, Kumarasamy N, Solomon S (1999): Subretinal cysticercosis in a patient with AIDS: treatment with xenon arc photocoagulation. *Retina* 19: 467–468.
- [20] Sihota R, Honavar SG. Oral albendazole in the management of extraocular cysticercosis. *Br J Ophthalmol*. 1994;78(8):621–623. doi: 10.1136/bjo.78.8.621.