

A rare case of unruptured ectopic pregnancy in a rudimentary horn with a dead foetus of Fifteen weeks: A Case Report

Dr. Venish Panchal

RMC Ajmer, Rajasthan, India

Abstract— *Pregnancy in non-communicating rudimentary horn is very rare and life threatening. It is often not diagnosed unless it terminates by rupture in the second trimester. Prerupture diagnosis of rudimentary horn pregnancy with USG is technically difficult, with sensitivity of 30%. Here a case of unruptured ectopic pregnancy in non-communicating rudimentary horn of unicornuate uterus at 15 weeks of gestation is presented. This patient presented in emergency department as a case of intrauterine fetal death. Laparotomy was carried out and excision of rudimentary horn was done.*

Keywords: *Ectopic Pregnancy, Rudimentary Horn, Unicornuate Uterus Foetal Death.*

I. INTRODUCTION

Ectopic pregnancy refers to the implantation of a fertilized egg in a location outside the uterine cavity, including the fallopian tubes, cervix, ovary, cornual region of the uterus, rudimentary horn of uterus, and abdominal cavity and broad ligament. The abnormally implanted fetus grows and draws its blood supply from the abnormal implantation site. As the fetus enlarges, it creates the potential for organ rupture because only the uterine cavity is designed by nature to expand and accommodate fetal development. The prevalence of unicornuate uterus in the general population is 0.1%.¹ A unicornuate uterus with a rudimentary horn is a rare mullerian abnormality in female resulting from defective fusion or resorption during embryonic life, which may cause many gynaecological and obstetrical complications like infertility, endometriosis, hematometra, abortions, and preterm deliveries; and is usually associated with urinary tract anomalies. Rudimentary horn is the rarest uterine anomaly and pregnancy in non communicating rudimentary horn is even rarer form of ectopic gestation Pregnancy in a non-communicating rudimentary horn is very difficult to diagnose before it ruptures, leading to life - threatening intraperitoneal hemorrhage, which usually presents in the second or third trimester. The only possible explanation for pregnancy to occur in this case is by trans-peritoneal migration of spermatozoa or embryo through contralateral tube. Incidence of rudimentary horn pregnancy is between 1 per 76000 to 1 per 140000 pregnancies.² While in sporadic cases a live infant may be delivered, most rudimentary horn pregnancies experience uterine rupture at 10- 15 weeks of gestation.³ Therefore early pre-rupture diagnosis is of major importance. We report a case of ectopic pregnancy in non-communicating rudimentary horn.

II. METHODOLOGY

A rare case of intrauterine fetal death was presented in emergency outdoor. Laprotomy was done and case was found of unruptured ectopic pregnancy in non-communicating rudimentary horn of unicornuate uterus at 15 weeks of gestation. Excision of rudimentary horn was done. As this case of ectopic pregnancy in rudimentary horn is very rare so case was studied thoroughly and case report was prepared to publish this rare case.

III. CASE REPORT

A 26 year old G2P1 patient presented to our hospital on 8/03/2014 with History of 4 months amenorrhoea with complaint abdominal pain for 2 days. Her last menstrual period was before 4 months. She had an AML of 7 years and had taken treatment for secondary infertility. Patient had history of diagnostic laparoscopy before 8 months at private hospital. Findings of laparoscopy were unicornuate uterus with right side horn non communicating with uterine cavity with no spillage on right side. Left side horn was developed with free spillage on that side. Excision of non-communicating horn was advised, but patient had refused. In the current pregnancy, the patient attended private consultant. After conception, owing to Intra uterine Fetal Death (IUFD), induction with PGE2 (Dinoprostone) Gel was done failing to which patient was referred to RMC, AJMER. On examination, she was vitally stable. On per abdomen examination, uterus corresponded to 14-16 weeks pregnancy. On per speculum examination cervix was normal. On per vaginum examination, cervix was firm, 2.5cm long and External Os was closed. There was no adnexal mass was felt. There was no bleeding or any discharge per vaginum.

On investigations, Haemoglobin 10.2 gm/dl, WBC 8300/cu.mm, Platelet count 3.08 lac/cu.mm and coagulation profile was normal. Transabdominal USG at Radiology department showed a single intrauterine pregnancy with absent cardiac activity having 15 weeks maturity. Generalised foetal oedema and effusion seen .A clinical impression of intrauterine fetal death was made. A repeat ultrasound was carried out by senior gynaecologist and co-related with previous laparoscopy findings, pregnancy in rudimentary horn was suspected. Patient was counselled and prepared for laparotomy.

3.1 Intra-operative findings

Foetus was in the right side non-communicating horn, right fallopian tube and ovary attached to right horn (figure I). Left horn of uterus with left fallopian tube and ovary were normal. Incision was given on right side non-communicating horn of uterus. A 14-16 weeks fetus was delivered out along with placenta and its membranes (figure II). Right side fallopian tube, ovarian ligament, round ligament were clamped, cut and doubly ligated. Right side non communicating horn excised from main uterus and defect was repaired in two layers .Postoperative period was uneventful .The stitches were removed and patient was discharged on 10 postoperative day. She was counseled about need for antenatal care and elective caesarean section for any future pregnancy. Rupture of pregnancy in the rudimentary horn by the 2 trimester is most common but silent rupture as the continuation of pregnancy as secondary abdominal pregnancy was reported by some studies. Cases of pregnancy progressing to the third trimester and resulting live birth after caesarean section have also been documented. A rudimentary horn pregnancy can never be delivered vaginally and mode of delivery is always a laparotomy. Surgical removal of the rudimentary horn is mandatory to avoid risk of uterine rupture with increased maternal morbidity. However laparoscopic excision of an unruptured rudimentary horn pregnancy has been increasingly carried out with safe and favorable outcome in many expert centers now. (Figure 1 & 2)

3.2 Histopathological Report

The gross specimen measured 6x5x3cm, endometrium and myometrium 0.4 and 0.6 cm in size. Uterine canal 4cm in length. Cervix not identified. Sections from uterus showed histology of retained products of conception and consistent with clinical diagnosis.

Figure 1
Unicornuate Uterus with Rudimentary Horn Pregnancy

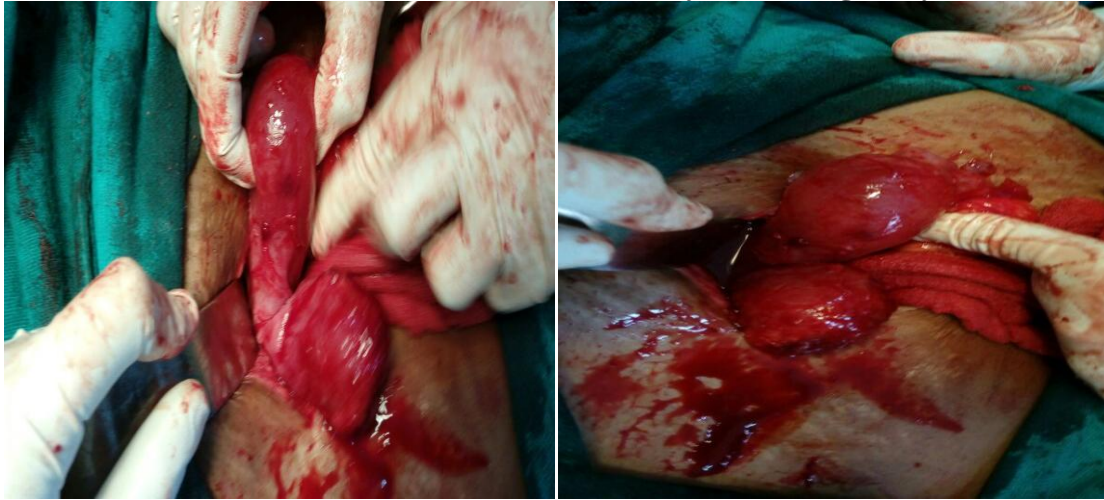
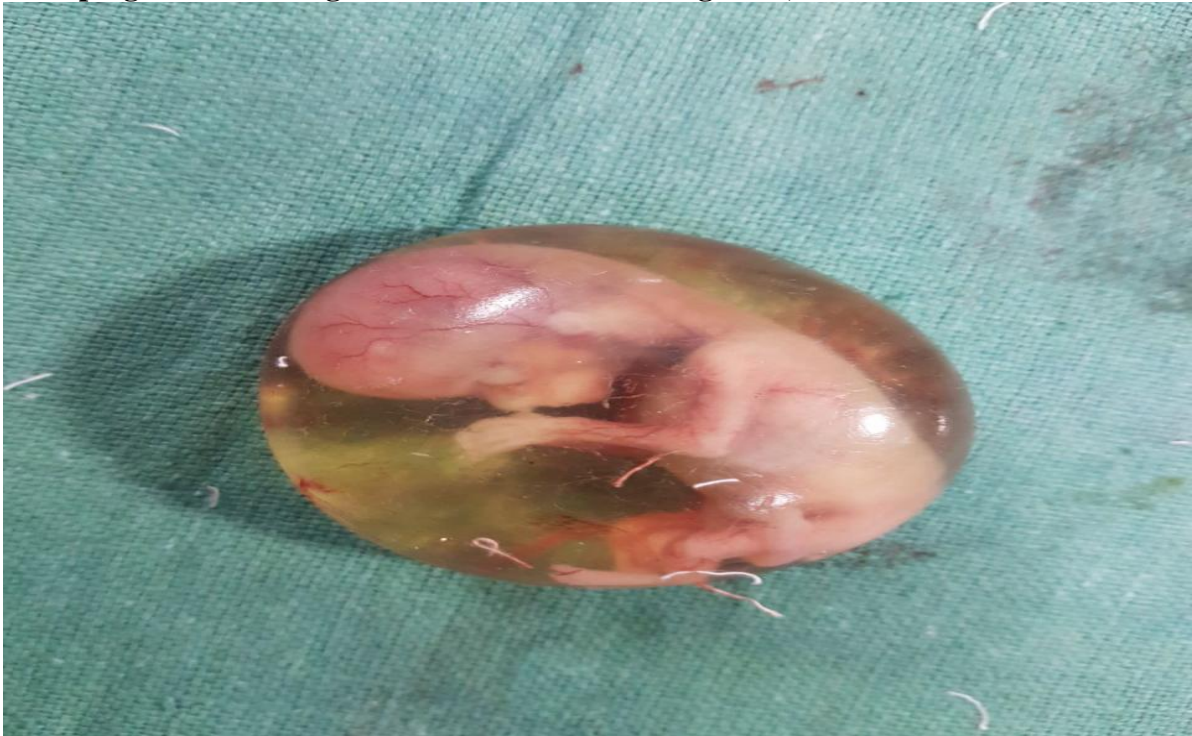

Figure 2
After keeping incision on right side non-communicating horn, a 14-16 week fetus delivered out



IV. DISCUSSION

Unicornuate uterus accounts for 2.4 - 13% of mullerian anomalies¹; 84% of cases have a contralateral rudimentary horn.⁴ Rudimentary horn with unicornuate uterus results from failure of complete development of one of the mullerian duct and incomplete fusion with the contralateral side. It is a class 2B anomaly according to the American Fertility Society Classification of Mullerian anomalies. In 83% of cases the rudimentary horn is non-communicating. The use of ultrasonography, CT scan, MRI, 3D ultrasonography and laparoscopy may be helpful for diagnosing such abnormalities.⁵ Tsafirir⁶ suggests criteria for the early diagnosis of rudimentary horn pregnancy:

- a. Pseudopattern of an asymmetrical bicornuate uterus,

- b. Absent visual continuity between the cervical canal and the lumen of the pregnant horn,
- c. Presence of myometrial tissue surrounding the gestational sac

Management consists of excision of the pregnant rudimentary horn and ipsilateral fallopian tube, traditionally by laparotomy. The first case of using laparoscopy was reported in 1996, and the horn was resected through a vaginal incision.⁷ With the advancement of laparoscopy, it may be an attractive option given the advantage of early recovery. However, in this case, the pregnant horn was approximately 7 - 8 cm, which was as large as the uterus proper, and therefore, laparotomy was the preferred choice for surgery. But when extensive resection of myometrium is required to preserve the uterus the surgical risk is high and the further risk of uterine rupture in subsequent pregnancy should be considered.^{8,9}

V. CONCLUSION

This case report highlighted the need for high level of suspicion of this rare entity. In this report we suggest criteria for early sonographic diagnosis of rudimentary horn pregnancy. High clinical suspicion, early diagnosis and timely laparotomy can reduce maternal morbidity and mortality. In our opinion, routine excision of rudimentary horn should be undertaken during non pregnant state. However, those women who refuse should be adequately counseled regarding potential complications and if pregnancy occurs in rudimentary horn, first trimester laparoscopic excision should be done.

CONFLICT OF INTEREST

None declared till now.

REFERENCES

- [1] Caserta D, Mallozzi M, Meldolesi C, Bianchi P, Moscarini M. Pregnancy in a unicornuate uterus: a case report. *J Med Case Rep* 2014;8:130
- [2] Johansen K. Pregnancy in a rudimentary horn: two case reports. *Obstet Gynecol* 1969; 34:805–808
- [3] Nahum GG. Rudimentary uterine horn pregnancy: a case report on surviving twins delivered eight days apart. *J Reprod Med* 1997; 42:525–532
- [4] Henriët E, Roman H, Zanati J, Lebreton B, Sabourin JC, Loïc M. Pregnant non-communicating rudimentary uterine horn with placenta percreta. *JSL* 2008; 12: 101-3
- [5] Marten K. MRI in the evaluation of mullerian duct anomalies. *Clin Imaging* 2003;27:346e50.
- [6] Tsafirir A, Rojansky N, Sela HY, Gomori JM, Nadjari M. Rudimentary horn pregnancy: first trimester prerupture sonographic diagnosis and confirmation by MRI. *J Ultrasound Med* 2005; 24: 219-23
- [7] Dulemba J. Laparoscopic management of a rudimentary horn pregnancy. *J Am Assoc Gynecol Laparosc* 1996;3:627e30
- [8] TeLinde's Operative Gynecology. 2011;10:816-7
- [9] Jeffcoate's Principles of Gynecology. 2014;8:144